

PennHIP Report

Referring Veterinarian: Dr Jeaneen Metzler	Clinic Name: Orangevale Veterinary Hospital
Email: orangevalevet@yahoo.com	Clinic Address: 6248 Main Ave #D Orangevale, CA 95662
	Phone: (916) 987-2055
	Fax: (916) 987-2052

Patient Information

Client: Spencer, Becky	Tattoo Num:
Patient Name: Fidelia Purple	Patient ID: MSCA:SBF6826/Fidelia Purple
Reg. Name:	Registration Num: MSCA:SBF6826
PennHIP Num: 138101	Microchip Num: 956000005146266
Species: Canine	Breed: MAREMMA SHEEPDOG
Date of Birth: 27 Aug 2019	Age: 18 weeks
Sex: Female	Weight: 50 lbs/22.7 kgs
Date of Study: 02 Jan 2020	Date Submitted: 04 Jan 2020
Date of Report: 06 Jan 2020	

Findings

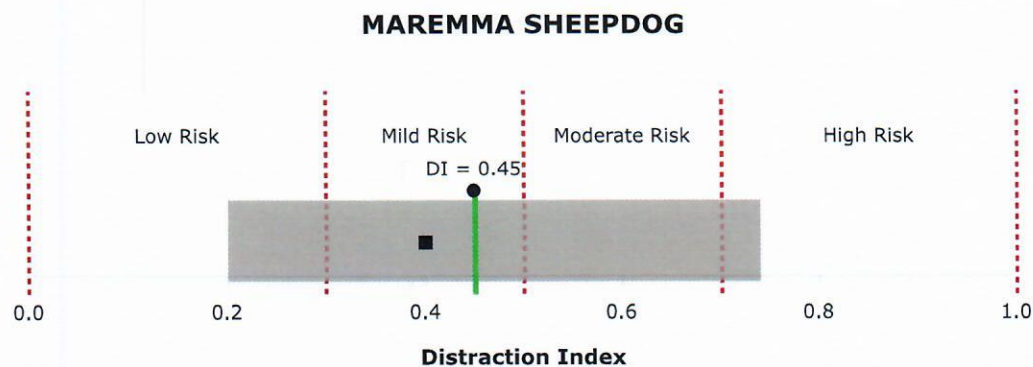
Distraction Index (DI): Right DI = 0.45, Left DI = 0.44.
 Osteoarthritis (OA): **No radiographic evidence of OA for either hip.**
 Cavitation/Other Findings: No cavitation present.

Interpretation

Distraction Index (DI): The laxity ranking is based on the hip with the greater laxity (larger DI). In this case the DI used is 0.45.

OA Risk Category: The DI is between 0.31 and 0.49. This patient is at mild risk for hip OA.

Distraction Index Chart:



BREED STATISTICS: This interpretation is based on a cross-section of 107 canine patients of the MAREMMA SHEEPDOG breed in the AIS PennHIP database. The gray strip represents the central 90% range of DIs (0.20 - 0.74) for the breed. The breed average DI is 0.40 (solid square). The patient DI is the solid circle (0.45).

SUMMARY: The degree of laxity (DI = 0.45) falls within the central 90% range of DIs for the breed. This amount of hip laxity places the hip at a mild risk to develop hip OA. **No radiographic evidence of OA for either hip.**